




## RESEARCH ARTICLE

# Proof of concept: Portable ultra-low-field magnetic resonance imaging for the diagnosis of epileptogenic brain pathologies

Tobias Bauer<sup>1,2,3</sup>  | Simon Olbrich<sup>1,2</sup> | Anne Groteklaes<sup>4</sup> | Nils Christian Lehnen<sup>1</sup> | Mousa Zidan<sup>1</sup> | Annalena Lange<sup>1,2,5,6</sup> | Justus Bisten<sup>1,2,5</sup> | Lennart Walger<sup>1,2</sup>  | Jennifer Faber<sup>3,7</sup> | Walter Bruchhausen<sup>6</sup> | Philipp Vollmuth<sup>1</sup> | Ulrich Herrlinger<sup>7</sup> | Alexander Radbruch<sup>1,3,8</sup> | Rainer Surges<sup>2</sup> | Hemmen Sabir<sup>3,4</sup> | Theodor Rüber<sup>1,2,3,8</sup> 

<sup>1</sup>Department of Neuroradiology, University Hospital Bonn, Bonn, Germany

<sup>2</sup>Department of Epileptology, University Hospital Bonn, Bonn, Germany

<sup>3</sup>German Center for Neurodegenerative Diseases (DZNE), Bonn, Germany

<sup>4</sup>Department of Neonatology and Pediatric Intensive Care, University Hospital Bonn, Bonn, Germany

<sup>5</sup>Institute for Computer Science, University of Bonn, Bonn, Germany

<sup>6</sup>Section for Global Health, Institute for Hygiene and Public Health, University Hospital Bonn, Bonn, Germany

<sup>7</sup>Department of Neurology, University Hospital Bonn, Bonn, Germany

<sup>8</sup>Center for Medical Data Usability and Translation, University of Bonn, Bonn, Germany

## Correspondence

Theodor Rüber, Department of Neuroradiology, Venusberg-Campus 1, University Hospital Bonn, Bonn 53127, Germany.

Email: [theodor.rueber@ukbonn.de](mailto:theodor.rueber@ukbonn.de)

## Funding information

Neuro-aCSis Bonn Neuroscience Clinician Scientist Program, Grant/Award Number: 2024-12-07

## Abstract

**Objective:** High-field magnetic resonance imaging (MRI) is a standard in the diagnosis of epilepsy. However, high costs and technical barriers have limited adoption in low- and middle-income countries. Even in high-income nations, many individuals with epilepsy face delays in undergoing MRI. Recent advancements in ultra-low-field (ULF) MRI technology, particularly the development of portable scanners, offer a promising solution to the limited accessibility of MRI. In this study, we present and evaluate the imaging capability of ULF MRI in detecting structural abnormalities typically associated with epilepsy and compare it to high-field MRI at 3 T.

**Methods:** Data collection was conducted within 3 consecutive weeks at the University Hospital Bonn. Inclusion criteria were a minimum age of 18 years, diagnosed epilepsy, and clinical high-field MRI with abnormalities. We used a .064 T Swoop portable MR Imaging System. Both high-field MRI and ULF MRI scans were evaluated independently by two experienced neuroradiologists as part of their clinical routine, comparing pathology detection and diagnosis completeness.

**Results:** Twenty-three individuals with epilepsy were recruited. One subject presented with a dual pathology. Across the entire cohort, in 17 of 24 (71%) pathologies, an anomaly colocalizing with the actual lesion was observed on ULF MRI. For 11 of 24 (46%) pathologies, the full diagnosis could be made based on ULF MRI. Tumors and posttraumatic lesions could be diagnosed best on ULF MRI, whereas cortical dysplasia and other focal pathologies were the least well diagnosed.

**Significance:** This single-center series of individuals with epilepsy demonstrates the feasibility and utility of ULF MRI for the field of epileptology. Its integration into epilepsy care offers transformative potential, particularly in resource-limited

Tobias Bauer and Simon Olbrich are shared first authors.

Hemmen Sabir and Theodor Rüber are shared senior authors.

This is an open access article under the terms of the [Creative Commons Attribution-NonCommercial](https://creativecommons.org/licenses/by-nc/4.0/) License, which permits use, distribution and reproduction in any medium, provided the original work is properly cited and is not used for commercial purposes.

© 2024 The Author(s). *Epilepsia* published by Wiley Periodicals LLC on behalf of International League Against Epilepsy.

settings. Further research is needed to position ULF MRI within imaging modalities in the diagnosis of epilepsy.

#### KEYWORDS

Epilepsy, Global Epileptology, limited resources, Neuroimaging, Sustainability

## 1 | INTRODUCTION

Magnetic resonance imaging (MRI) is a mainstay in the diagnosis of epilepsy, enabling the visualization of potentially epileptogenic brain lesions.<sup>1,2</sup> Conventional MRI devices operate at field strengths between 1.5 and 3 T. In the diagnostic workup of epilepsy, MRI is trending toward higher field strengths such as 3 T (high field [HF]) or 7 T (ultra-high field),<sup>3,4</sup> in the hope that the high field strength will also allow smaller potentially epileptogenic lesions to be better detected or described. These anticipations are bolstered by previous research showing the superiority of 3 T over 1.5 T MRI for epilepsy imaging<sup>5,6</sup> and by the first 7 T MRI studies in individuals with epilepsy.<sup>7,8</sup> The high cost and complex infrastructure requirements of HF MRI or ultra-high-field MRI often limit their accessibility, particularly in resource-constrained settings. This is why the vast majority of the approximately 50 000 MRI scanners worldwide are located in high-resource countries, such as those in North America, Western Europe, and parts of East Asia.<sup>9</sup> Here, the density of MRI scanners can be quite high, often ranging from 10 to >40 MRI units per million people. In contrast, in low-resource countries, especially in parts of Africa, Southeast Asia, and Latin America, the number can be as low as .1–1 MRI unit per million people.<sup>10</sup> In 2019, 11 countries in Africa had no MRI scanners.<sup>9</sup> Approximately 80% of people with epilepsy live in low- and middle-income countries.<sup>11</sup> Barriers in access to MRI exacerbate the challenges faced in providing optimal care for people with epilepsy in low- and middle-income regions. Globally, up to 90% of all people with epilepsy lack access to MRI.<sup>12</sup> However, also in high-resource countries, not all people with epilepsy undergo MRI, as it is generally recommended, and many have it delayed.<sup>13,14</sup>

Recent advancements in imaging technology have led to the development of portable ultra-low-field (ULF) MRI systems,<sup>15–17</sup> which operate at substantially lower magnetic field strength and do not require helium cooling. These systems are by far less expensive to purchase and maintain. Therefore, ULF MRI systems hold promise for expanding the accessibility of neuroimaging in various settings, including resource-limited environments and point-of-care diagnostics.<sup>18</sup> The feasibility of ULF MRI has been shown in a number of environments,<sup>17,19–21</sup> including intensive care settings<sup>22,23</sup> and for the detection of

#### Key points

- High-field MRI is a standard in the diagnosis of epilepsy but has limited accessibility.
- Ultra-low-field MRI offers a solution with portable and less expensive devices potentially beneficial for underserved areas.
- This study compares the diagnostic yield of ultra-low-field to high-field MRI in 23 individuals with epilepsy.
- Two thirds of pathologies could be localized on ultra-low-field MRI, and in half of the cases full diagnosis was possible.
- Ultra-low-field MRI may play a crucial role in the diagnosis of epilepsy, both globally and as a complement in high-income countries.

stroke.<sup>17,24</sup> However, ULF MRI has not yet been deployed for the diagnosis of epilepsy. Yet, the application of ULF MRI scanners presents a unique opportunity to bridge the gap in diagnostic capabilities between well-resourced and limited-resource settings in epileptology.

This proof-of-concept study investigates the clinical utility of ULF MRI for the diagnosis of epilepsy. We aim to present and evaluate the imaging capability of ULF MRI in detecting structural abnormalities typically associated with epilepsy and compare it to HF MRI in a clinical routine setting with two neuroradiologists. We hypothesize that the diagnostic yield of ULF MRI is lower than that of HF MRI but not as low as may be expected intuitively.

## 2 | MATERIALS AND METHODS

### 2.1 | Cohort recruitment

For 3 consecutive weeks (in May 2024), all adults with epilepsy who presented at the Department of Neuroradiology, University Hospital Bonn, for a clinical HF MRI at 3 T as part of their clinical assessment and had a HF MRI-visible lesion were invited to have an additional ULF MRI scan. All exclusion criteria relevant for ULF MRI were already covered by the exclusion criteria for a clinical HF

MRI examination (e.g., pacemakers, MRI-incompatible implants). The study was approved by the institutional review board of the University Hospital Bonn. All participants provided written informed consent.

## 2.2 | Clinical HF MRI routine protocol

Clinical HF MRI scans were performed using a 3 T MRI scanner (Achieva, Philips Healthcare). Our routine epilepsy protocol, which adheres to international consensus recommendations, includes at least a three-dimensional (3D) T1-weighted sequence (.9 mm), 3D fluid-attenuated inversion recovery (FLAIR; 1 mm), and axial and coronal T2-weighted sequences.<sup>14</sup> Depending on the clinical indication, other sequences (e.g., diffusion-weighted or susceptibility-weighted) were added and gadolinium-based contrast agents were applied. The scan duration ranged from 24 to 52 min (median = 31 min).

## 2.3 | ULF MRI protocol

ULF MRI scans were acquired using a .064 T Swoop Portable MR Imaging System (Hyperfine). The protocol provided by the manufacturer included 3D T1-weighted and T2-weighted sequences, axial and coronal FLAIR, and axial diffusion-weighted images. The total scanning time was 48 min 16 s. Sequence parameters are detailed in Table 1. If contrast agents were used in the clinical routine scan, ULF MRI was performed not earlier than 24 h thereafter to be considered nonenhanced. If ULF MRI was performed immediately after a contrast-enhanced clinical MRI, it was considered contrast-enhanced. Figure 1 shows an example of an ULF MRI scanning setup.

## 2.4 | Image quality evaluation

To compare image quality between ULF MRI and HF MRI, we ran FSL FAST on the T1-weighted scans to segment gray

and white matter and estimate the bias field.<sup>25</sup> Four metrics were calculated: (1) *bias-field magnitude*—difference between maximum and minimum value of the bias-field estimated in FSL FAST, (2) *gray matter signal-to-noise ratio*—average gray matter signal divided by SD of background noise (all voxels outside the head), (3) *white matter signal-to-noise ratio*—average white matter signal divided by SD of background noise, and (4) *contrast-to-noise ratio*—difference between average gray and white matter signals divided by SD of background noise. These metrics were compared between ULF MRI and HF MRI using two-sided paired *t*-tests.

## 2.5 | Image assessment

Clinical HF MRI scans were evaluated as part of the clinical routine by a radiology resident and a consultant neuroradiologist. ULF MRI scans were assessed by a different radiology resident and a consultant neuro-radiologist who were not involved in reading the clinical HF MRI scans and were blinded to the results of the clinical HF MRI. Both sets of readers were provided with the same clinical information to ensure a consistent context of assessment. We used two operational categories to assess whether a clinical HF MRI-visible pathology was detected on ULF MRI: (1) *anomaly found*—this indicates that a finding deviating from that on the clinical HF MRI, which aligns anatomically with the true lesion, was detected; for example, a cavernoma described as a “hyperintense lesion” or “unspecific defect” on ULF MRI would fall into this category; and (2) *full diagnosis*—this means that all relevant information from the clinical HF MRI reading was also present in the ULF MRI report.

## 3 | RESULTS


### 3.1 | Study cohort

Twenty-three individuals with epilepsy were recruited. One subject presented with a dual pathology. The median

**TABLE 1** Scanning protocol used for the ULF MRI.

Sequence	Orientation	In-plane resolution, mm	Slice thickness, mm	TR, ms	TE, ms	TI, ms	Duration, min:s
T1w	3D	2.2	2.2	1000	4.75	270	9:46
T2w	3D	2.2	2.2	2000	148.16	NA	10:04
FLAIR	Axial	1.7	5	3500	162.18	1301.11	8:59
FLAIR	Coronal	1.7	5	3500	168.60	1296.56	9:06
DWI	Axial	2.4	5.9	1000	80.3	NA	10:21

Abbreviations: 3D, three-dimensional; DWI, diffusion-weighted imaging; FLAIR, fluid-attenuated inversion recovery; NA, not applicable; T1w, T1-weighted; T2w, T2-weighted; TE, echo time; TI, inversion time; TR, repetition time.



**FIGURE 1** A person with epilepsy undergoes imaging in the hyperfine ultra-low-field scanner at the bedside.

age at MRI was 36 years (range = 18–84); 11 participants were male (48%), and 12 participants were female (52%). In one case, a clinical HF MRI was scheduled after ULF MRI but could not be performed for organizational reasons. In this case, the clinical HF MRI closest to the ULF MRI performed 116 days earlier was used for the analysis. In the remaining cases, median absolute difference between clinical HF MRI and ULF MRI was 1 day (range = 0–36); both scans were performed the same day in seven cases (30%). Sixteen ULF MRI scans were carried out in a clinical examination room; six individuals were scanned in the patient's room on the ward. There were no complications or adverse events during deployment of the ULF MRI. See [Table 2](#) for clinical details of all individuals.

### 3.2 | Image quality

The bias-field magnitude was significantly larger on ULF MRI than HF MRI (mean = .97 vs. .27,  $t_{22} = 6.54$ ,  $p < .001$ ; [Figure 2A](#)). Both gray and white matter signal-to-noise ratios, as well as the contrast-to-noise ratio, were significantly lower on ULF MRI than HF MRI (gray matter: 44.5 vs. 103.4,  $t_{44} = 8.34$ ,  $p < .001$ , [Figure 2B](#); white matter: 78.2 vs. 158.0,  $t_{22} = 6.65$ ,  $p < .001$ , [Figure 2C](#); contrast: 33.8 vs. 54.6,  $t_{22} = 3.64$ ,  $p = .001$ , [Figure 2D](#)).

### 3.3 | Detection rate

Across the entire cohort, in 17 of 24 (71%) pathologies, an anomaly colocalizing with the actual lesion was observed on ULF MRI (Category 1). For 12 of 24 (50%) pathologies,

the full diagnosis could be made based on ULF MRI (Category 2). Note that the number of lesions adds to 24, not 23, because two different pathologies (meningioma and cavernoma) were observed in Case 2. Please see [Figure 2E](#) for a visualization of detection rates in all subgroups. In three of 24 cases (13%), findings on ULF MRI were identified exclusively by the consultant neurologist and missed by the neuroradiology resident.

### 3.4 | Mesiotemporal pathologies

Clinical HF MRI showed mesiotemporal pathologies in four individuals (Cases 12, 16, 17, and 18). Of the individuals diagnosed with unilateral hippocampal sclerosis (Cases 12 and 16), the typical pattern with unilateral hippocampal volume loss and hyperintensity was only observed in one participant on ULF MRI (Case 16; [Figure 3A](#)), whereas the other case was diagnosed to be nonlesional (Case 12). Unilateral hippocampal hyperintensity was observed concordantly on clinical HF MRI and ULF MRI (Case 18; [Figure 3B](#)). Bilateral hippocampal sclerosis was reported on clinical HF MRI in another participant (Case 17), whereas only bilateral hippocampal hyperintensity was observed on ULF MRI. Taken together, mesiotemporal hyperintensity was consistently found in three of four cases, whereas volume loss was observed in only one of three cases on ULF MRI.

### 3.5 | Neocortical malformations

Clinical HF MRI revealed neocortical malformations in three cases (Cases 1, 3, and 5), two of which had a focal



TABLE 2 Patient cohort and MRI reading.

ID	Age, years	Sex	Etiology	Semiology	Clinical HF MRI findings	ULF MRI findings
1	25	M	Focal cortical dysplasia	Focal aware tonic (right arm)	Focal cortical dysplasia, left frontal	Nonlesional
2	29	F	Unknown	Focal impaired awareness behavioral arrest, focal to bilateral tonic-clonic	Left thalamic defect	Left thalamic defect
3	18	F	Polymicrogyria	Focal impaired awareness tonic-clonic (left), focal to bilateral tonic-clonic	Polymicrogyria right frontal	Nonlesional
4	48	M	Unknown	Focal aware sensorimotor (right arm and leg) with aura	Left hemiatrophy with caudate nucleus atrophy	Left hemiatrophy with caudate nucleus atrophy
5	23	M	Focal cortical dysplasia	Focal impaired awareness behavioral arrest	Focal cortical dysplasia, left frontopolar	Nonlesional
6	19	F	Cavernoma	Focal aware sensory visual, focal to bilateral tonic-clonic	Left temporoparietal cavernoma (14 mm)	Left temporoparietal hyperintense lesion
7	46	M	Cystic lesion	Focal impaired awareness orofacial automatism	Cystic lesion, right temporal (4 mm)	Nonlesional
8	36	F	Rasmussen syndrome	Focal aware hemiconic, focal impaired awareness sensory-visual	Left frontal defect	Left frontal defect
9	59	M	Posttraumatic	Focal impaired awareness motor	Bilateral frontobasal and right occipital defects	Bilateral frontobasal and right occipital defects
10	84	F	Meningioma, cavernoma	Focal impaired awareness	Multiple bilateral frontal meningiomas and left frontal cavernoma	Multiple bilateral frontal meningiomas and associated brain lesions
11	31	F	Cavernoma	Focal impaired awareness orofacial automatism, focal to bilateral tonic-clonic	Left occipital cavernoma (18 mm)	Left occipital hyperintense lesion
12	55	M	Hippocampal sclerosis	Focal impaired awareness orofacial automatism, focal to bilateral tonic-clonic	Right hippocampal sclerosis	Nonlesional
13	33	M	Post-NORSE	Focal impaired awareness sensory-auditory, focal to bilateral tonic-clonic	Supra- and infratentorial microbleeds	Nonlesional
14	48	M	Posttraumatic	Focal impaired awareness behavioral arrest, focal to bilateral tonic-clonic	Left frontobasal defect, old subdural hematoma	Left frontobasal defect
15	18	F	Hamartoma	Focal impaired awareness with laughing (gelastic)	Tuber cinereum hamartoma (7 mm)	Nonlesional
16	45	F	Hippocampal sclerosis	Focal impaired awareness tonic (right arm)	Left hippocampal sclerosis	Left hippocampal sclerosis
17	36	F	Hippocampal sclerosis	Focal to bilateral tonic-clonic	Bilateral hippocampal sclerosis	Bilateral mesiotemporal hyperintensity

(Continues)

TABLE 2 (Continued)

ID	Age, years	Sex	Etiology	Semiology	Clinical HF MRI findings	ULF MRI findings
18	25	F	Unknown	Focal aware sensory–vestibular	Hyperintensity in right hippocampus	Hyperintensity in right hippocampus
19	69	F	Cerebral metastatic bronchial carcinoma	Focal impaired awareness motor	Left frontal and parietal lesions with surrounding edema	Left frontal and parietal lesions with surrounding edema
20	36	M	Glioblastoma	Focal aware autonomic with nausea	Right-frontal space-occupying lesion, surrounding edema, midline shift	Right-frontal space-occupying lesion, surrounding edema, midline shift
21	61	F	Unspecified brain tumor	Focal aware motor	Multiple right-hemispheric space-occupying lesions, midline shift	Multiple right-hemispheric space-occupying lesions
22	72	M	Low-grade glioma	Absence	Right-mesiotemporal space-occupying lesion	Right-mesiotemporal space-occupying lesion
23	65	M	Posttraumatic	Focal impaired awareness tonic	Right frontal defect, periventricular leukoencephalopathy, microbleeds supra- and infratentorial	Right frontal defect, periventricular leukoencephalopathy, microbleeds supra- and infratentorial

Abbreviations: F, female; HF, high field; M, male; MRI, magnetic resonance imaging; NORSE, new onset refractory status epilepticus; ULF, ultra-low-field.

cortical dysplasia (Case 1 [Figure 3C] and Case 5) and one had a polymicrogyria (Case 3; Figure 3D). None of these three pathologies was visible on ULF MRI.

3.6 | Other focal nonprogressive pathologies

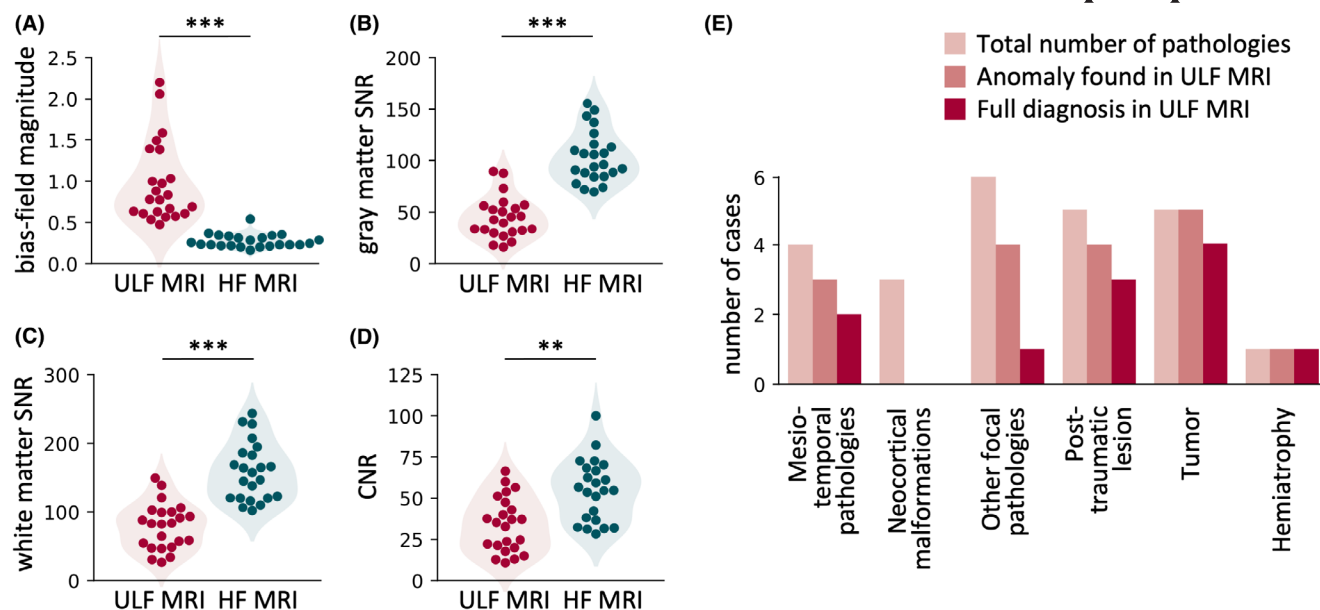
Other focal nonprogressive pathologies were found in six individuals (Cases 2, 6, 7, 10, 11, and 15) using clinical HF MRI. It showed cavernomas with typical characteristics, including a T2-hypointense rim and a reticulated core of heterogeneous signal intensity in three individuals (Cases 6, 10, and 11). Two cavernomas were described as T2-hyperintense lesions (Cases 6 and 11; Figure 3E) on ULF MRI. In the third individual (Case 10), the cavernoma was described as an unspecific brain lesion associated with an adjacent meningioma. The typical characteristics of a cavernoma, however, were not visible on ULF MRI in any of these individuals. Furthermore, a left thalamic defect (Case 2) was also seen on ULF MRI, but a small cystic lesion (3 × 4 mm, Case 7; Figure 3F) and a small tuber cinereum hamartoma (7 mm, Case 15) were not detected on ULF MRI. Taken together, anomalies were found in four of six (Category 1), but full diagnosis was made in only one of six (Category 2).

3.7 | Posttraumatic lesions

Five participants showed posttraumatic lesions on clinical HF MRI (Cases 8, 9, 13, 14, and 23). In all cases with defects (Cases 8, 9, 14, and 23), the defect area was as well visible on ULF MRI (see Figure 4A,B). What was not observed on ULF MRI but was on clinical MRI, however, was supra- and infratentorial microbleeds in an individual after new onset refractory status epilepticus (Case 13) and the small remainder of an old subdural hematoma (Case 14). Thus, full diagnosis was made in three of five (Category 2).

3.8 | Tumors

Five individuals presented with tumor-associated epilepsy (Cases 10, 19, 20, 21, and 22). Specifically, multiple meningiomas could be identified as such using ULF MRI (Case 10; Figure 4E). In this case, the ULF MRI scan was performed immediately after the contrast-enhanced clinical HF MRI and the ULF MRI T1-weighted sequence was started 27 min after contrast agent injection. In the four other cases (Cases 19–22; including cerebral



**FIGURE 2** Image quality and detection rates for each subgroup of pathologies. (A) Comparison of bias-field magnitude, (B) gray matter signal-to-noise ratio (SNR), (C) white matter SNR, and (D) contrast-to-noise ratio (CNR) between ultra-low-field (ULF) magnetic resonance imaging (MRI), and high field (HF) MRI. (E) For each of the six pathology groups as identified on HF MRI (mesiotemporal pathologies, neocortical malformations, other focal pathologies, posttraumatic lesions, tumor, hemiatrophy), the graph reads as follows. Left bar: Total number of pathologies. Middle bar: Number of pathologies where an anomaly colocalizing with the actual lesion was observed (Category 1). Right bar: Number of pathologies where full diagnosis was made based on ULF MRI (Category 2). Images from all cases are presented in Data S1.  $**p = .001$ ,  $***p < .001$ .

metastases, low-grade glioma, and glioblastoma), the space-occupying tumor mass could be detected on non-enhanced ULF MRI, as well as the surrounding edema (see Figure 4C,D). A midline shift was reported on clinical HF MRI in two individuals but was only detected in one of two cases on ULF MRI (Case 20; see Figure 4C). Taking this into account, anomalies (Category 1) were found in all cases, but full diagnosis was made in only four of five (Category 2).

### 3.9 | Hemiatrophy

Case 4 presented with hemiatrophy and caudate nucleus atrophy, which is indicative for Rasmussen syndrome despite the atypical onset age. A biopsy to confirm this diagnosis, however, has not yet been performed. The MRI characteristics were visible on both the clinical HF MRI and ULF MRI (Category 2; Figure 4F).

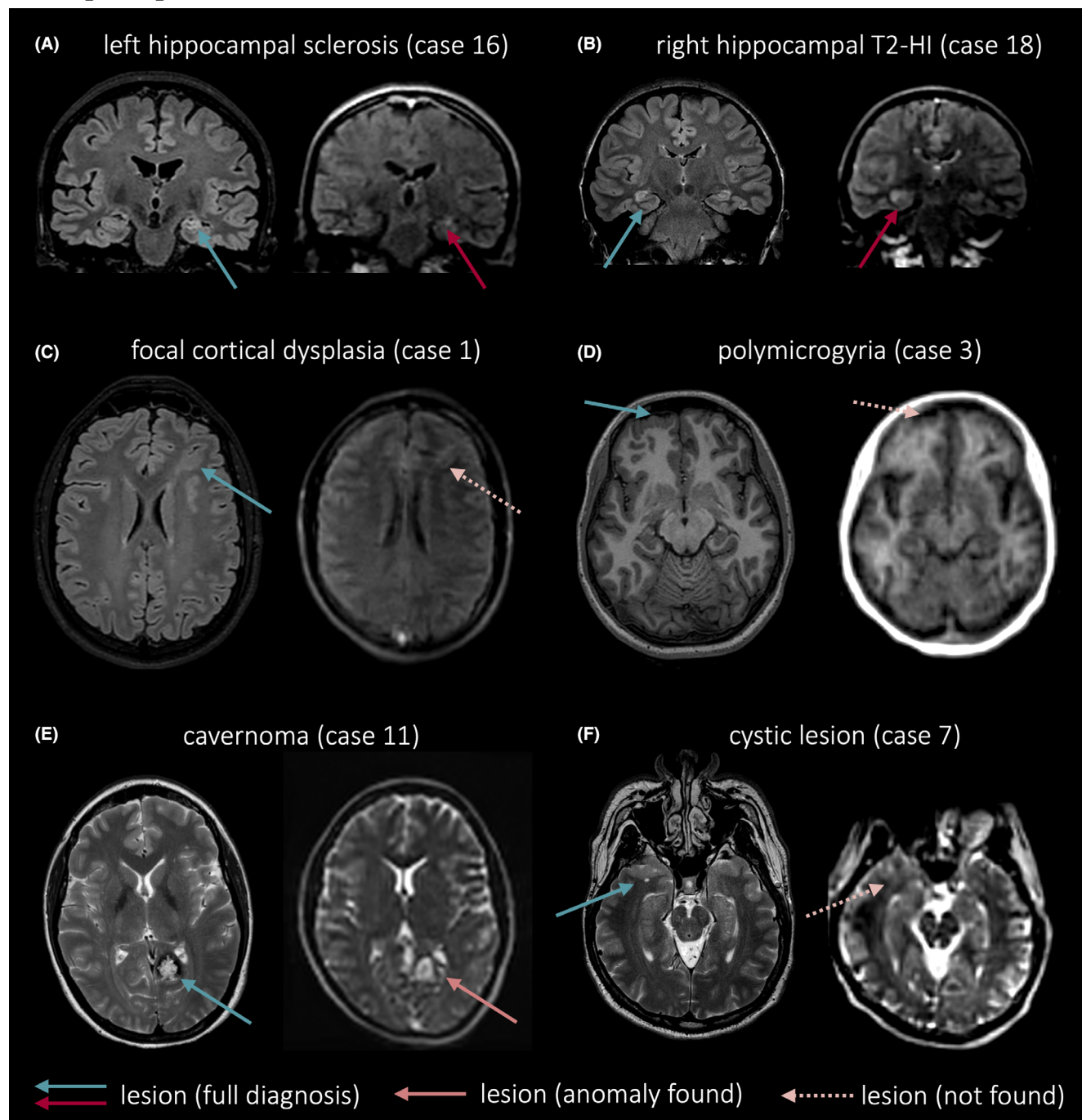
## 4 | DISCUSSION

Our findings demonstrate for the first time the deployment of ULF MRI in epileptology. We report the diagnostic value of ULF MRI as compared to clinical HF MRI in the diagnosis of epilepsy. In this limited cohort, roughly

two thirds (17/24, 71%) of potentially epileptogenic pathologies known from clinical HF MRI can be detected on ULF MRI, and a complete diagnosis is possible in approximately half of the cases (11/24, 46%).

However, we note that the diagnostic yield of ULF MRI is different for different pathologies. Unsurprisingly, hemispheric pathologies like hemispheric atrophy or large pathological entities like tumors or posttraumatic lesions can be diagnosed well; anomalies were found in 10 of 11 cases, and full diagnosis was possible in eight of 11 cases. The diagnosis of more focal pathologies such as cortical dysplasia was more difficult on ULF MRI; still, anomalies were found in four of nine cases, but full diagnosis was possible in only one of nine cases. In mesiotemporal pathologies, hippocampal FLAIR hyperintensity was consistently found in three of four cases, whereas volume loss was observed in only one of three cases on ULF MRI. This may indicate that ULF MRI has a higher sensitivity for detecting hippocampal FLAIR hyperintensity compared to hippocampal volume loss.

Although the diagnostic yield of ULF MRI in our study appears to be moderate, it should not be omitted that our study only includes individuals with epilepsy and abnormal HF MRI, whereas half of individuals with epilepsy show normal HF MRI.<sup>5,26-28</sup> With the estimated sensitivity of 71% and an assumed near perfect specificity for ULF MRI (i.e., assuming that ULF MRI produces minimal



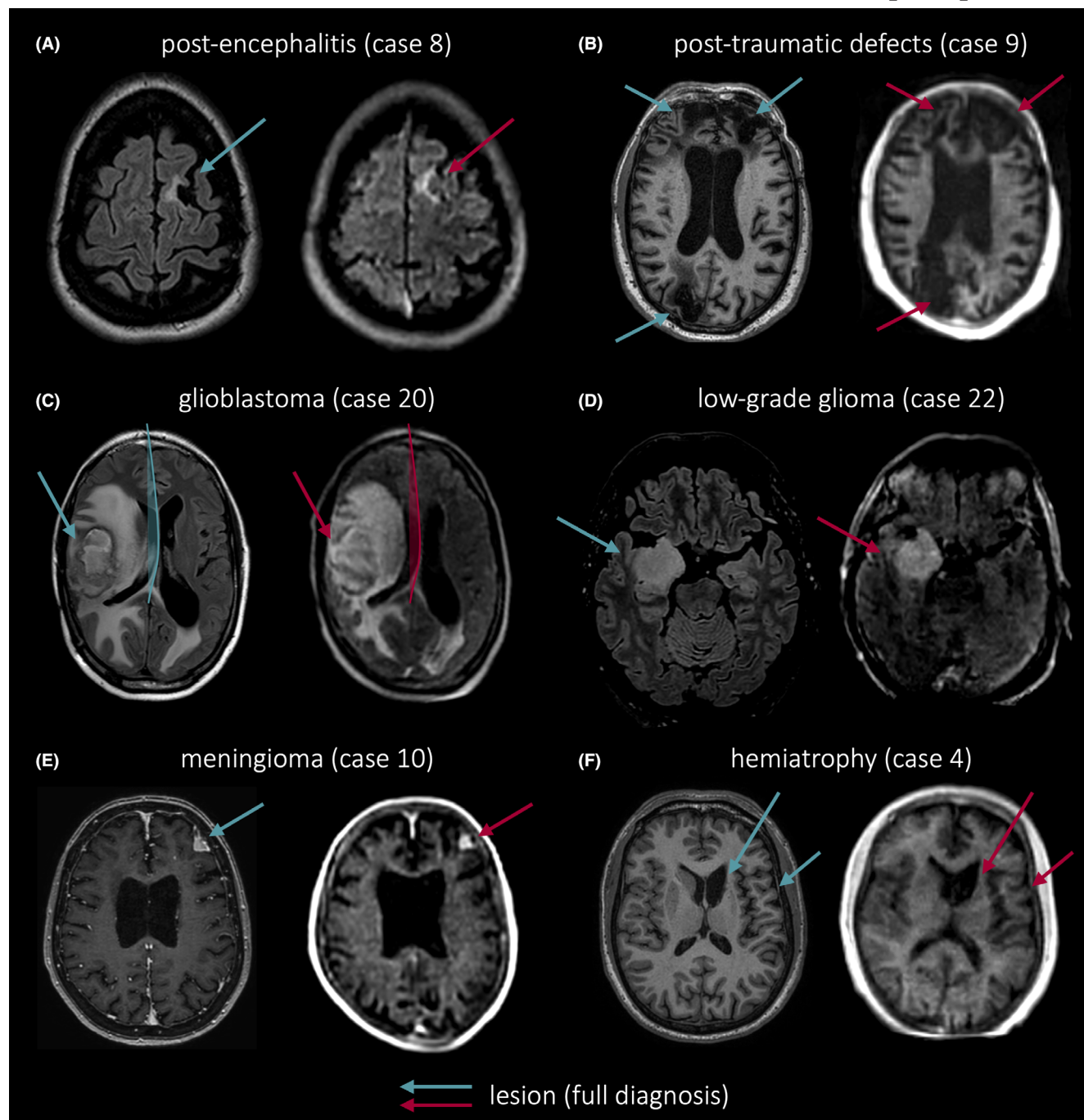
**FIGURE 3** Comparison of clinical high field (HF) magnetic resonance imaging (MRI) and ultra-low-field (ULF) MRI for selected cases with typical epileptogenic lesions. In all panels, clinical HF MRI is shown on the left, and ULF MRI is shown on the right. (A) Coronal fluid-attenuated inversion recovery (FLAIR): left hippocampal sclerosis. (B) Coronal FLAIR: right hippocampal T2 hyperintensity (HI). (C) Axial FLAIR: focal cortical dysplasia. (D) Axial T1-weighted: polymicrogyria. (E) Axial T2-weighted (T2w): cavernoma. (F) Axial T2w: cystic lesion. Arrows mark the relevant lesions; dotted arrows are used when the lesion was not found in neuroradiological readings of ULF MRI.

false-positive results), the diagnostic accuracy could potentially exceed 80%. This makes ULF MRI a predestined screening method.

However, given the current evidence regarding sensitivity and specificity, this remains pure speculation. The main limitation of this study is the single-center design and the limited size of the cohort. Furthermore, our study

is limited in that it only included individuals with known MRI abnormalities on clinical HF MRI and in that we were not able to directly compare interrater agreement between HF MRI and ULF MRI. Further studies should be conducted in a multicenter setting, involve a larger cohort, and use standardized reporting to quantify diagnostic accuracy and interrater reliability. Moreover, these studies





**FIGURE 4** Comparison of clinical high field (HF) magnetic resonance imaging (MRI) and ultra-low-field (ULF) MRI for selected individuals with posttraumatic and tumor-associated epilepsy. In all panels, clinical HF MRI is shown on the left, and ULF MRI is shown on the right. (A) Axial fluid-attenuated inversion recovery (FLAIR): focal postencephalitis lesion associated with Rasmussen syndrome. (B) Axial T1-weighted (T1w): multiple posttraumatic defects. (C) Axial FLAIR: glioblastoma; solid line illustrates midline shift toward the left hemisphere. (D) Axial FLAIR: low-grade glioma of right amygdala. (E) Axial contrast-enhanced T1w: meningioma; ULF MRI scan was 27 min after contrast agent injection. (F) Axial T1w: left caudate atrophy and insular/temporal hemiatrophy suggesting Rasmussen syndrome. Arrows mark the relevant lesion.

should subspecialize on ULF MRI after the first seizure or its application in presurgical evaluation in addition to clinical HF MRI. Particularly, the prospective inclusion of individuals irrespective of known MRI abnormalities is warranted.

Furthermore, it will be necessary in the future to make computer-aided image processing methods accessible for ULF MRI. Two approaches are conceivable here: on the one hand, dedicated postprocessing to adapt the image quality of ULF MRI to conventional MRI,<sup>29–31</sup> on the other

hand, an optimization of the algorithms to the image quality of ULF MRI.<sup>32–34</sup>

In epileptology, it is often intuitively and wrongly assumed that the clinical value of MRI is linearly related to its field strength. However, 7 T is neither per se “more than twice as good” as 3 T, nor does the diagnostic significance of .064 T appear to be only a few percent of that. Rather, the diagnostic advantage is incremental from .064 T through 1.5 T and 3 T to 7 T, and each field strength has its own advantages and disadvantages. In the case of .064 T, advantages are lower cost, smaller footprint, enhanced accessibility, lower power, and fewer safety risks. The disadvantages include lower signal-to-noise ratio, decreased resolution, increased scan time, and reduced gray/white matter contrast.<sup>15,35</sup> In addition, geometric inaccuracies can occur with ULF MRI, which preclude its use for critical applications such as stereotaxis in its current state of development. As the global availability of high field-strength is elusive in the medium term and the epilepsy community is challenged both by the unmet global needs of individuals with epilepsy and by the general imperative of sustainability,<sup>36</sup> it will be the subject of future studies to establish and validate a triagelike system in which individuals with epilepsy are directed to MRI facilities according to their expected clinical need and the accessibility of these systems. Subject to further development of ULF scanners, the application of ULF MRI is imaginable also in high-income countries and cases with low clinical urgency for imaging to save the cost- and resource-intensive HF and ultra-high-field MRI. Additionally, ULF MRI could vanquish barriers of intraoperative MRI for some procedures due to reduced requirements for radiofrequency shielding, operational safety, 5 G line distance, and increased magnetic resonance compatibility for traditional surgical implements.<sup>15,37,38</sup>

In summary, this single-center series of individuals with epilepsy demonstrates the feasibility and utility of ULF MRI for the field of epileptology. Its integration into epileptological care offers transformative potential, particularly in resource-limited settings. As innovation continues, portable ULF MRI will enable the democratization of MRI and open up new applications not previously feasible with conventional systems,<sup>39</sup> thereby improving the diagnosis, treatment, and overall management of epilepsy, ultimately reducing the global burden of this condition and achieving more global health equity. Further research is required in prospective multicenter studies to delineate pathology-specific detection rates, quantify the reliability of established biomarkers, and test the validity of routinely used diagnostic algorithms.

## ACKNOWLEDGMENTS

We thank the Ultra Low Field Neuroimaging in the Young Consortium for providing the Hyperfine Swoop System. T.B. is funded by the Neuro-aCSis Bonn Neuroscience Clinician Scientist Program (2024-12-07). P.V. is funded through an Else Kröner Clinician Scientist Endowed Professorship by the Else Kröner-Fresenius Foundation (2022\_EKCS.17).

## CONFLICT OF INTEREST STATEMENT

P.V. has received consulting fees and stock options from Need, and honoraria for lectures from Bayer and advisory board participation for Cercare Medical, outside the submitted work. A.R. serves on the scientific advisory boards for GE Healthcare, Bracco, Bayer, Guerbet, and AbbVie; has received speaker honoraria from Bayer, Guerbet, Siemens, and Medscape; and is a consultant for, and has received institutional study support from, Guerbet and Bayer. R.S. has received personal fees as a speaker or for serving on advisory boards from Angelini, Arvelle, Bial, Desitin, Eisai, Jazz Pharmaceuticals Germany, Janssen-Cilag, LivaNova, LivAssured, Novartis, Precisis, Rapport Therapeutics, Tabuk Pharmaceuticals, UCB Pharma, UNEEG, and Zogenix. He is an editorial board member of *Epilepsy and Behavior* and associate editor of *Epilepsia Open*. These activities were not related to the content of this article. None of the other authors has any conflict of interest to disclose. We confirm that we have read the Journal's position on issues involved in ethical publication and affirm that this report is consistent with those guidelines.

## DATA AVAILABILITY STATEMENT

The data that support the findings of this study are available on request from the corresponding author. The data are not publicly available due to their containing information that could compromise the privacy of research participants.

## ORCID

Tobias Bauer  <https://orcid.org/0000-0002-0555-6214>

Lennart Walger  <https://orcid.org/0000-0002-3300-6877>

Theodor Rüber  <https://orcid.org/0000-0002-6180-7671>

## REFERENCES

1. Bianchin MM, Wichert-Ana L, Velasco TR, Martins APP, Sakamoto AC. Imaging epilepsy with SISCO. *Nat Rev Neurol*. 2011;7:240.
2. Cendes F, Theodore WH, Brinkmann BH, Sulc V, Cascino GD. Neuroimaging of epilepsy. *Neuroimaging Part II*. Elsevier; 2016. p. 985–1014 Available from: <https://doi.org/10.1016/B978-0-444-53486-6.00051-X>

3. Ladd ME, Quick HH, Speck O, Bock M, Doerfler A, Forsting M, et al. Germany's journey toward 14 tesla human magnetic resonance. *MAGMA*. 2023;36(2):191–210. [cited 2024]; Available from: <https://pubmed.ncbi.nlm.nih.gov/37029886/>
4. Rüber T, David B, Elger CE. MRI in epilepsy: clinical standard and evolution. *Curr Opin Neurol*. 2018;31(2):1–231.
5. Winston GP, Micallef C, Kendell BE, Bartlett PA, Williams EJ, Burdett JL, et al. The value of repeat neuroimaging for epilepsy at a tertiary referral centre: 16 years of experience. *Epilepsy Res*. 2013;105(3):349–55.
6. Knake S, Triantafyllou C, Wald LL, Wiggins G, Kirk GP, Larsson PG, et al. 3T phased array MRI improves the presurgical evaluation in focal epilepsies: a prospective study. *Neurology*. 2005;65(7):1026–31.
7. Opheim G, Van Der Kolk A, Bloch KM, Colon AJ, Davis KA, Henry TR, et al. 7T epilepsy task force consensus recommendations on the use of 7T MRI in clinical practice. *Neurology*. 2021;96(7):327–41. [cited 2024]; Available from: <https://pubmed.ncbi.nlm.nih.gov/33361257/>
8. Wang I, Oh S, Blümcke I, Coras R, Krishnan B, Kim S, et al. Value of 7T MRI and post-processing in patients with nonlesional 3T MRI undergoing epilepsy presurgical evaluation. *Epilepsia*. 2020;61(11):2509–20. [cited 2024]; Available from: <https://pubmed.ncbi.nlm.nih.gov/32949471/>
9. Geethanath S, Vaughan JT. Accessible magnetic resonance imaging: a review. *J Magn Reson Imaging*. 2019;49(7):e65–e77. [cited 2024]; Available from: <https://pubmed.ncbi.nlm.nih.gov/30637891/>
10. Magnetic resonance imaging units (per million population), total density. 2024 [cited 2024]. Available from: <https://www.who.int/data/gho/data/indicators/indicator-details/GHO/total-density-per-million-population-magnetic-resonance-imaging>
11. Beghi E, Giussani G, Abd-Allah F, Abdela J, Abdelalim A, Abraha HN, et al. Global, regional, and national burden of epilepsy, 1990–2016: a systematic analysis for the global burden of disease study 2016. *Lancet Neurol*. 2019;18(4):357–75. [cited 2024]; Available from: <https://pubmed.ncbi.nlm.nih.gov/30773428/>
12. Murali S, Ding H, Adedeji F, Qin C, Obungoloch J, Asllani I, et al. Bringing MRI to low- and middle-income countries: directions, challenges and potential solutions. *NMR Biomed*. 2024;37(7):e4992 [cited 2024]; Available from: <https://pubmed.ncbi.nlm.nih.gov/37401341/>
13. Wang I, Bernasconi A, Bernhardt B, Blumenfeld H, Cendes F, Chinvarun Y, et al. MRI essentials in epileptology: a review from the ILAE imaging taskforce. *Epileptic Disord*. 2020;22(4):421–37. [cited 2024]; Available from: <https://onlinelibrary.wiley.com/doi/full/10.1684/epd.2020.1174>
14. Bernasconi A, Cendes F, Theodore WH, Gill RS, Koepp MJ, Hogan RE, et al. Recommendations for the use of structural magnetic resonance imaging in the care of patients with epilepsy: a consensus report from the international league against epilepsy neuroimaging task force. *Epilepsia*. 2019;60(6):1054–68. [cited 2024]; Available from: <https://pubmed.ncbi.nlm.nih.gov/31135062/>
15. Arnold TC, Freeman CW, Litt B, Stein JM. Low-field MRI: clinical promise and challenges. *J Magn Reson Imaging*. 2023;57(1):25–44. [cited 2024]; Available from: <https://pubmed.ncbi.nlm.nih.gov/36120962/>
16. Parasuram NR, Crawford AL, Mazurek MH, et al. Future of Neurology & Technology: neuroimaging made accessible using low-field, portable MRI. *Neurology*. 2023;100(22):1067–71. [cited 2024]; Available from: <https://pubmed.ncbi.nlm.nih.gov/36720639/>
17. Prabhat AM, Crawford AL, Mazurek MH, et al. Methodology for low-field, portable magnetic resonance neuroimaging at the bedside. *Front Neurol*. 2021;12:760321 [cited 2024]; Available from: [www.frontiersin.org](http://www.frontiersin.org)
18. Shen FX, Wolf SM, Bhavnani S, Deoni S, Elison JT, Fair D, et al. Emerging ethical issues raised by highly portable MRI research in remote and resource-limited international settings. *NeuroImage*. 2021 [cited 2024]; Available from: <https://pubmed.ncbi.nlm.nih.gov/34062266/>;238:118210.
19. Shellock FG, Rosen MS, Webb A, et al. Managing patients with unlabeled passive implants on MR systems operating below 1.5 T. *J Magn Reson Imaging*. 2024;59(5):1514–22. [cited 2024]; Available from: <https://pubmed.ncbi.nlm.nih.gov/37767980/>
20. Altaf A, Baqai MWS, Urooj F, Alam MS, Aziz HF, Mubarak F, et al. Utilization of an ultra-low-field, portable magnetic resonance imaging for brain tumor assessment in lower middle-income countries. *Surg Neurol Int*. 2023;14:260 [cited 2024]; Available from: <https://pubmed.ncbi.nlm.nih.gov/37560587/>
21. Deoni SCL, Medeiros P, Deoni AT, Burton P, Beauchemin J, D'Sa V, et al. Development of a mobile low-field MRI scanner. *Sci Rep*. 2022;12(1):5690 [cited 2024]; Available from: <https://pubmed.ncbi.nlm.nih.gov/35383255/>
22. Sheth KN, Mazurek MH, Yuen MM, Cahn BA, Shah JT, Ward A, et al. Assessment of brain injury using portable, low-field magnetic resonance imaging at the bedside of critically ill patients. *JAMA Neurol*. 2020;78(1):41–7. [cited 2024]; Available from: <https://pubmed.ncbi.nlm.nih.gov/32897296/>
23. Cho SM, Wilcox C, Keller S, Acton M, Rando H, Etchill E, et al. Assessing the SAFETY and FEASIBILITY of bedside portable low-field brain magnetic resonance imaging in patients on ECMO (SAFE-MRI ECMO study): study protocol and first case series experience. *Crit Care*. 2022;26(1):119 [cited 2024]; Available from: <https://pubmed.ncbi.nlm.nih.gov/35501837/>
24. Sorby-Adams A, Guo J, de Havenon A, et al. Diffusion-weighted imaging fluid-attenuated inversion recovery mismatch on portable, low-field magnetic resonance imaging among acute stroke patients. *Ann Neurol*. 2024;96(2):321–31. [cited 2024]; Available from: <https://pubmed.ncbi.nlm.nih.gov/38738750/>
25. Zhang Y, Brady M, Smith S. Segmentation of brain MR images through a hidden Markov random field model and the expectation-maximization algorithm. *IEEE Trans Med Imaging*. 2001;20(1):45–57.
26. Duncan JS, Winston GP, Koepp MJ, Ourselin S. Brain imaging in the assessment for epilepsy surgery. *The Lancet Neurology*. 2016;15:420–33.
27. Sidhu MK, Duncan JS, Sander JW. Neuroimaging in epilepsy. *Curr Opin Neurol*. 2018;31(4):371–8. Available from: <http://insights.ovid.com/crossref?an=00019052-900000000-99118>
28. Hakami T, McIntosh A, Todaro M, et al. MRI-identified pathology in adults with new-onset seizures. *Neurology*. 2013;81(10):920–7.
29. Donnay C, Okar SV, Tsagkas C, Gaitán MI, Poorman M, Reich DS, et al. Super resolution using sparse sampling at portable ultra-low field MR. *Front Neurol*. 2024;15:1330203.

30. Cooper R, Hayes RA, Corcoran M, Sheth KN, Arnold TC, Stein JM, et al. Bridging the gap: improving correspondence between low-field and high-field magnetic resonance images in young people. *Front Neurol*. 2024 [cited 2024];15:1339223.
31. Iglesias JE, Schleicher R, Laguna S, Billot B, Schaefer P, McKaig B, et al. Quantitative brain morphometry of portable low-field-strength MRI using super-resolution machine learning. *Radiology*. 2023;306(3):e220522.
32. Billot B, Magdamo C, Cheng Y, Arnold SE, Das S, Iglesias JE. Robust machine learning segmentation for large-scale analysis of heterogeneous clinical brain MRI datasets. *Proc Natl Acad Sci USA*. 2023;120(9):e2216399120.
33. Arnold TC, Tu D, Okar SV, Nair G, By S, Kawatra KD, et al. Sensitivity of portable low-field magnetic resonance imaging for multiple sclerosis lesions. *Neuroimage Clin*. 2022;35:103101.
34. Váša F, Bennallick C, Bourke NJ, Padormo F, Baljer L, Briski U, et al. Ultra-low-field brain MRI morphometry: test-retest reliability and correspondence to high-field MRI. *bioRxiv*. 2024; [cited 2024]. Available from: <https://www.biorxiv.org/content/10.1101/2024.08.14.607942v1>
35. Campbell-Washburn AE, Keenan KE, Hu P, Mugler JP 3rd, Nayak KS, Webb AG, et al. Low-field MRI: a report on the 2022 ISMRM workshop. *Magn Reson Med*. 2023;90(4):1682–94. [cited 2024]; Available from: <https://pubmed.ncbi.nlm.nih.gov/37345725/>
36. Sisodiya SM, Fowler HJ, Lake I, Nanji RO, Gawel K, Esguerra CV, et al. Climate change and epilepsy: time to take action. *Epilepsia Open*. 2019;4(4):524–36. [cited 2024]; Available from: <https://onlinelibrary.wiley.com/doi/full/10.1002/epi4.12359>
37. Altaf A, Shakir M, Malik MJA, Arif A, Islam O, Mubarak F, et al. Intraoperative use of low-field magnetic resonance imaging for brain tumors: a systematic review. *Surg Neurol Int*. 2023;14:357 [cited 2024]; Available from: [/pmc/articles/PMC10629339/](https://pmc/articles/PMC10629339/).
38. Altaf A, Baqai MWS, Urooj F, Alam MS, Aziz HF, Mubarak F, et al. Intraoperative use of ultra-low-field, portable magnetic resonance imaging—first report. *Surg Neurol Int*. 2023;14:212 [cited 2024]; Available from: [/pmc/articles/PMC10316138/](https://pmc/articles/PMC10316138/).
39. Kimberly WT, Sorby-Adams AJ, Webb AG, Wu EX, Beekman R, Bowry R, et al. Brain imaging with portable low-field MRI. *Nat Rev Bioeng*. 2023;1(9):617–30. [cited 2024]; Available from: <https://www.nature.com/articles/s44222-023-00086-w>

## SUPPORTING INFORMATION

Additional supporting information can be found online in the Supporting Information section at the end of this article.

**How to cite this article:** Bauer T, Olbrich S, Groteklaes A, Lehnen NC, Zidan M, Lange A, et al. Proof of concept: Portable ultra-low-field magnetic resonance imaging for the diagnosis of epileptogenic brain pathologies. *Epilepsia*. 2024;65:3607–3618. <https://doi.org/10.1111/epi.18171>